Anatomy of

Female Reproductive System

Femal Reproductive System

Learning Objectives:

By the end of this lecture the nursing student will be able to:

1. Describe the parts of external, internal organ of female reproductive system (FRS) and breast.
2. Explain the function of the major external and internal organ of female reproductive system and breast.

Outlines:

1. External Organs (Vulva):

- 1. Mons Veneries.
  2. Labia Majora.
  3. Labia Minora.
  4. Clitoris.
  5. Vestibule.
  6. Bartholoin's Glands.
  7. Perineum.

B. Internal Organs:

1. Vagina.
2. Uterus.
3. Fallopian Tubes.
4. Ovaries.
5. Breast.

Introduction

The female reproductive anatomy includes parts inside and outside the body. The function of the external female reproductive structures (the genitals) is: To enable sperm to enter the body and to protect the internal genital organs from infectious organisms.

Femal Reproductive System

The functions of the female reproductive system include:

1. Production of female gametes (ova).
2. Production of female sex hormones (estrogens and progesterone).
3. Reception and maintenance of a developing embryo and fetus.

External Anatomy of Woman

Collectively, the external female reproductive organs are called the Vulva

Vulvar ***Anatomy***

- ➔ The vulva is a portal for a variety of functions (reproductive and excretory) and has a unique role in sexual feelings and function.
- ➔ Because it is covered with both dry, squamous skin and moist mucous membrane, it is subject to diseases affecting both.
- ➔ Because of the close proximity of the rectum, intestinal bacteria are more or less constantly present to some degree.

External Female reproductive Structures:

- ☞ Mons Pubis.
- ☞ Labia Majora.
- ☞ Labia Minora.
- ☞ Clitoris.
- ☞ Vestibule.
- ☞ Perineum.

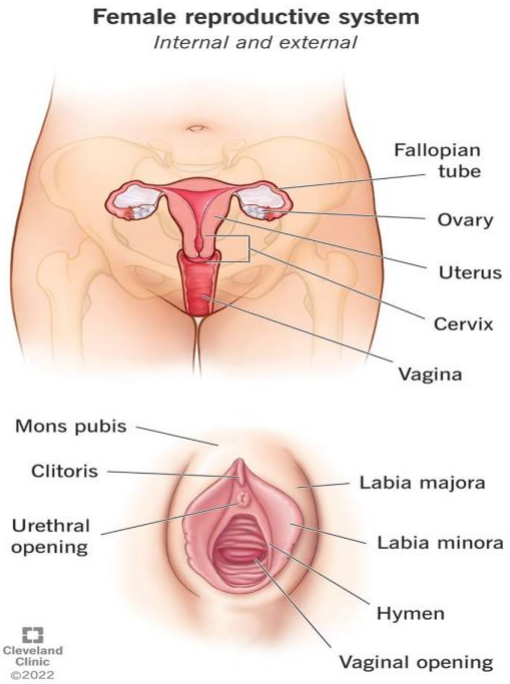

1) Mons Pubis:

✍ The triangular mound of fatty tissue that covers the pubic bone over the symphysis pubis covered with pubic hair from the time of puberty

- It protects the pubic symphysis. After puberty, it covered with hair.
- The Mons is the anterior fusion of the Labia Majora.

2) Labia Majora (Greater lips or larger lips):

- There are two rounded, fleshy folds of tissue that extended from the mons pubis **to** the perineum.
- The labia majora enclose and protect the other external reproductive organs.
- The labia majora are comparable to the scrotum in males
- The labia majora contain sweat and oil-secreting glands.
- After puberty, the labia majora are covered with hair.

3) Labia Minora (Lesser lips or small lips):-

- These are two thin folds of skin lying between the labia Majora.
- It is very small or up to 2 inches wide.
- They lie just inside the labia majora, and surround the openings to the vagina and urethra.
- Anteriorly, they divided to enclose the clitoris, and posteriorly they fuse, forming the fourchette.
- The labia minora come together at the top of the vulva to form the clitoral hood.
- The glands in the labia minora serve to lubricate the vulva.

4) Clitoris:-

- It is a sensitive **erectile organ** responsible for sexual sensations corresponding to male penis.

- It has three parts: root, body and glans.
- The clitoris is covered by a fold of skin, called the prepuce.
- Located at the most superior part of the vulvar vestibule, the clitoris is surrounded by the anterior part of the labia minora.
- It is rich with blood and nerve endings supply, so, it is very sensitive and vascular and plays a role in the orgasm of sexual intercourse.

5) Vestibule

- It is **oval-shaped area** formed between the labia minora, clitoris, and fourchette and Bartholins glands.
- This perineal area contains the vaginal orifice, opening of the female urethra and the openings for the excretory ducts of the greater and lesser vestibular glands.

Vestibular glands

There are three types of glands that open into the vestibule:

- The greater vestibular (Bartholin's) glands are found on each side of the vestibule.
- The lesser vestibular glands are located between the urethral and vaginal orifices. These glands are homologous to the male prostate.
- Vestibular bulb: a pair of subcutaneous erectile tissues analogous to the penile bulb . They extend on each side of the vestibule and join in front of the urethral orifices.

6) Perineum

- It is the most posterior part of the external female reproductive organs.
- It extends from fourchette anteriorly to the anus posteriorly.
- it is composed of fibrous and muscular tissues that support pelvic structures

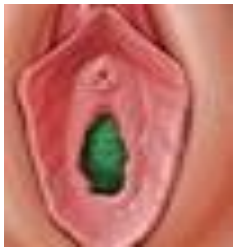

** Hymens

- When the labia are spread open, the hymen or remnants of the hymen are visualized. This ring-like structure is usually torn at first intercourse, leading to a small amount of bleeding.
- Anatomic variation with hymens is considerable. Some are thin, stretchy, and so small as to be largely unnoticed. Others are thick and nearly impenetrable.

- Rarely, the hymen completely covers the vaginal opening, disallowing the passage of menstrual products.

7) Perineum

- The perineum is the most posterior part of the external female reproductive organs.The muscle and tissue located between the vaginal opening and anal canal
- It supports and surrounds the lower parts of the urinary and digestive tracts
- The perineum contains an abundance of nerve endings that make it sensitive to touch
- An episiotomy is an incision of the perineum used during childbirth for widening the vaginal opening.

Female Internal Reproductive Organs

The female internal genital organs include the vagina, uterus, uterine tubes and ovaries

1) Vagina (the birth canal)

Structure:

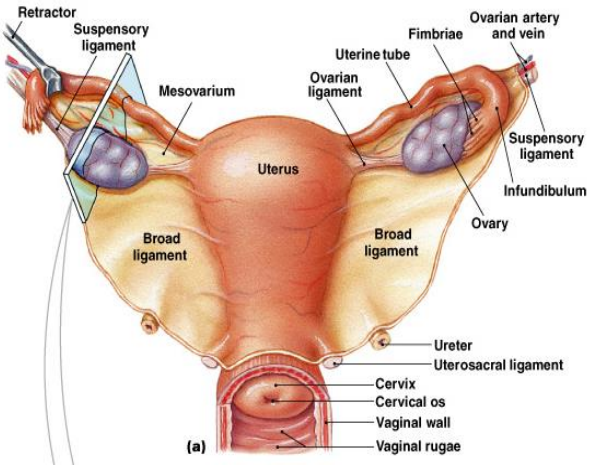

- The vagina is a canal that extends from the cervix of the uterus to the vestibule of the vagina
- The vagina communicates **superiorly with the cervical canal** and **opens inferiorly** into the vestibule of the vagina.
- The posterior wall is 10 cm long; the anterior wall is only 8 cm.
- It is **fibromuscular tube** or sheath lined with **stratified squamous epithelium**. tissue capable of great distension, it is elevated into folds **(rugae).**
- **Bartholin's glands**:-are located besides the vaginal opening and produce a fluid (mucus) secretion.
- It forms the inferior portion of the **female genital tract** and the **birth canal**.

- It is divided into **anterior**, **posterior**, and **lateral parts**. The **posterior part** of the **fornix** is the **deepest** where the cervix of the uterus enters its cavity and is related to the **rectouterine pouch**.
- The **posterior wall** is about **1 cm longer** than the **anterior wall** and is in contact with the **external uterine ostium** (external os).

- The uterus lies almost at a **right angle** to the **axis of the vagina** (anteverted position). This **uterine angle** increases as the urinary bladder **fills**.
- The **vaginal recess** around the cervix is called the **fornix**.
- The reaction of the vagina is acidic; the **pH is 4.5** that protect the vagina against infection.

Functions:

1. As a passageway which allows the escape of the menstrual flow
2. For uterine secretions to pass down through the introitus
3. As the birth canal during labor
4. With the help of two Bartholin's glands becomes lubricated during coitus
5. It receives the penis and the ejected sperm during sexual intercourse.

Vaginal relation: The vagina is located

- **posterior to the** urinary bladder
- **Anterior to the** rectum
- **Superior** with the cervical canal
- **Inferiorly** into the vestibule of the vagina.
- In the anatomical position, the vagina **runs** obliquely **upwards and backwards** at **45 °** angle.

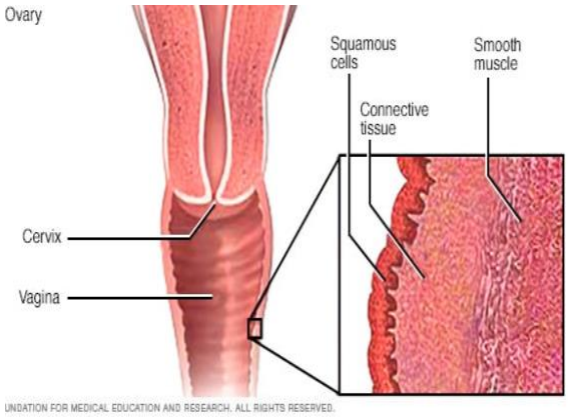

2) Uterus (womb)

Structure:

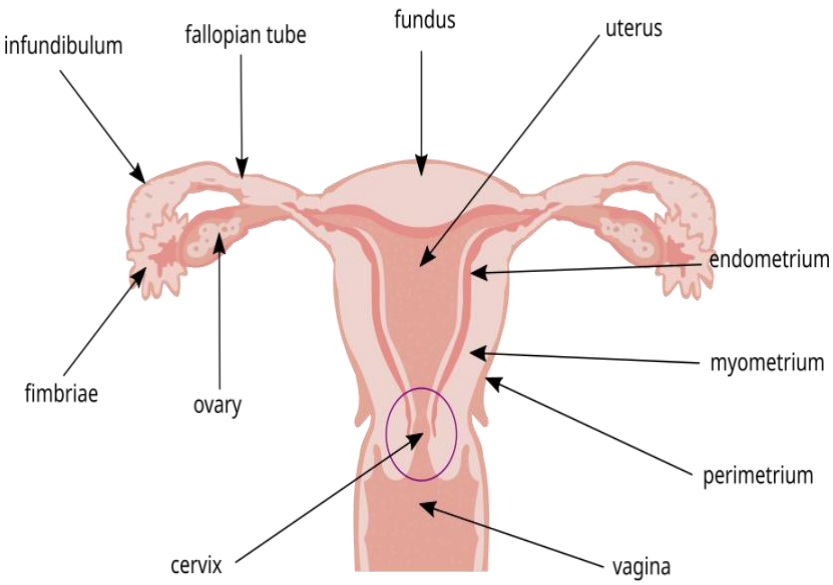

- This is a **hollow**, **thick-walled**, **pear-shaped muscular organ** located behind the bladder and in front of the rectum.
- It is **7 to 8 cm** long, **5 to 7 cm wide**, and **2 to 3 cm**. The weight of the uterus is 60- 70 gms. In non-pregnant women.

Position:

- It is situated in the cavity of the true pelvis, behind the bladder and in front of the rectum. The normal uterus is anteverted and anteflexed.
- Anteversion: The uterus is bent forwards at right angle to the vagina. The angle between the long axis of cervix and the long axis of vagina is called the angle of anteversion (90°).
- Anteflexion: The body of uterus is slightly bent forwards on the cervix and the angle between the long axis of body of uterus and the long axis of cervix is known as angle of anteflexion (125°).

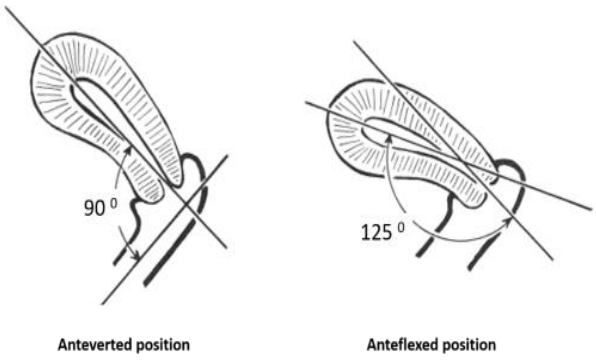

https://i0.wp.com/www.anatomyqa.com/wp-content/uploads/2017/06/retroverted-and-retroflexed-uterus.png?resize=385%2C371

The uterus is divided into **three parts**

- **Corpus**.
- **Isthmus**.
- **The cervix.**

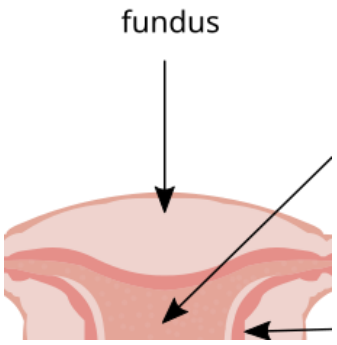

1- The Fundus of the Uterus (corpus)

- The **fundus** of the uterus is the **rounded superior part** of the **body**.
- It is located **superior** to the line joining the points of entrance of the uterine tubes.
- The regions of the body **where the uterine tubes enter** are called the **cornua.**

2 -The Isthmus of the Uterus:

- This is about 1 cm long and is the narrow transitional zone between the body and cervix.
- This slight constriction is **most obvious** in **nulliparous women**.

3 -Cervix

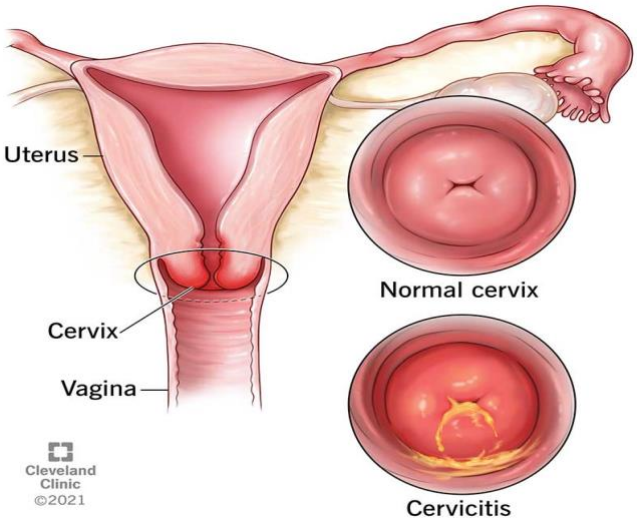

- Extends from the isthmus (constricted portion of the uterus) into the vagina.
- As the cervix projects into the vagina, it is divided into vaginal and supravaginal parts.
- The rounded vaginal part communicates with the vagina via the external ostium of the uterus
- **The ostium** is bounded by **anterior** and **posterior lips** formed by the **cervix**.
- **Internal Os**: opening of the cervix into the isthmus
- **External Os**: opening of the cervix into the vagina
- **Cervical canal**: Area between internal and external Os Measures approximately **4 cm.**

The Wall of the Uterus:

The wall of the uterus consists of 3 layers:

1. **Perimetrium**
   - ☞ **The outer serous coat** ,
   - ☞ Consists of peritoneum supported by a thin layer of connective tissue.

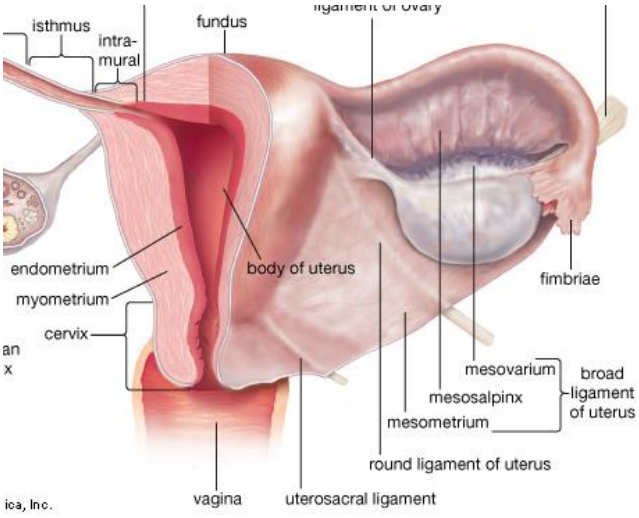

2. **Myometrium**
   - ☞ It is the middle muscle coat, thick in the upper part of the uterus and thin in the isthmus and cervix.
   - ☞ It is consists of 12 to 15 mm of smooth muscle.
   - ☞ The myometrium increases greatly during pregnancy.
   - ☞ The main branches of the blood vessels and nerves of the uterus are located in this layer;
3. **Endometrium**
   - ☞ The inner lining of the epithelium (mucous membrane).
   - ☞ Mucous coat firmly adherent to the underlying myometrium.
   - ☞ Sheds during menstruation, it lines only the body of the uterus.

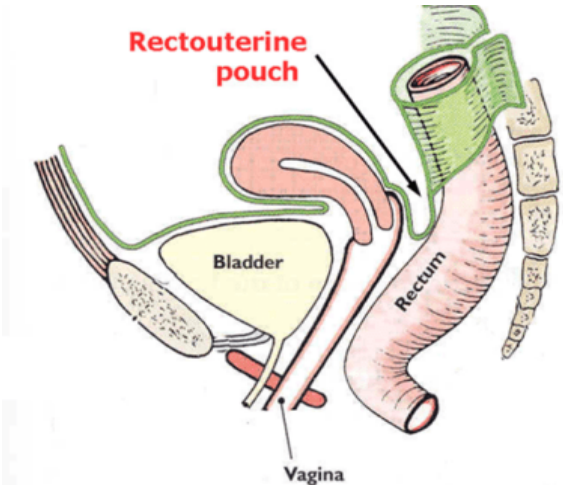

Relations of the uterus

1. **Anteriorly** : the base of the bladder
2. **Posteriorly**: the Pouch of Douglas which separate uterine body from rectum

https://i0.wp.com/www.anatomyqa.com/wp-content/uploads/2017/06/location-of-uterus.png?resize=376%2C342

3. **Laterally**:

a- The uterine tubes and ovaries

b- Broad ligament

4. **Superiorly** : loops of intestine

5. **Inferiorly** : the vagina

The Ligaments of the Uterus

The ligaments of the uterus are eight in number: one anterior; one posterior; two lateral or broad; two uterosacral; and two round ligaments.

1. **Transverse Cervical Ligament (Cardinal Ligament)**

   This extends from the **cervix** and **lateral parts** of the **vaginal fornix** to the lateral walls of the pelvis.

2. **The Uterosacral Ligaments :**

   These pass **superiorly** and **slightly posteriorly** from the **sides of the cervix** to the **middle of the sacrum**. The uterosacral ligaments tend to hold the cervix in its normal relationship to the sacrum.

3. **The Round Ligament of the Uterus**

   These ligaments are **10 to 12 cm** long and extend for the **lateral aspect** of the **uterus**, passing anteriorly between the layers of the broad ligament. They leave the **abdominal cavity** through the inguinal canal and insert into the labia majora.

4. **The Broad Ligament**

- This is a **fold of peritoneum** with **mesothelium** on its **anterior** and **posterior surfaces**.
- It extends from the **sides of the uterus** to the lateral walls and floor of the pelvis.
- It **holds the uterus in its normal position**.
- The **2 layers** of the broad ligament are **continuous with each other** at a **free edge**. This is **directed anteriorly** and **superiorly** to surround the uterine tube.
- **Laterally**, the broad ligament is **prolonged superiorly** over the **ovarian vessels** as the **suspensory ligament of the ovary**.

- The broad ligament contains **extraperitoneal tissue** (connective tissue and smooth muscle) called **parametrium**.

3) Ovaries

Structure

The ovaries are small, oval-shaped glands that are located on either side of the uterus.

Medulla:

➔ • It is the supporting framework, which is made of fibrous tissue, ovarian blood vessels, lymphatic and nerves transfer through it.

Cortex:

➔ • It is the functioning part of the ovary contains the ovarian follicles in different stages of development.

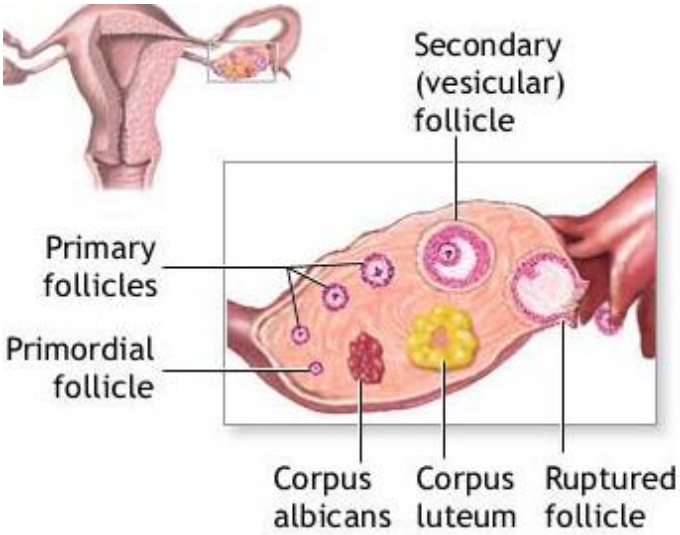

Each ovary consists of the following parts:

1. The **germinal epithelium** is a layer of simple epithelium (low cuboidal or squamous) that covers the surface of the ovary.
2. ***The*** **tunica albuginea** is a whitish capsule of dense irregular connective tissue located immediately deep to the germinal epithelium.
3. **The ovarian cortex** is a region just deep to the tunica albuginea. It consists of ***ovarian follicles***
4. ***The*** **ovarian medulla** is deep to the ovarian cortex. The border between the cortex and medulla is indistinct, but the medulla consists of more loosely arranged connective tissue and contains blood vessels, lymphatic vessels and nerves.
5. ***Ovarian follicles*** are in the cortex and consist of ***oocytes*** in various stages of development, plus the cells surrounding them. When the surrounding cells form a single layer, they are called ***follicular cells***; later in development, when they form

several layers, they are referred to as ***granulosa cells***. The surrounding cells nourish the developing oocyte and begin to secrete estrogens as the follicle grows larger.

6. **A mature (Graafian) follicle** is a large, fluid-filled follicle that is ready to rupture and expel its secondary oocyte, a process known as ***ovulation***.
7. **A corpus luteum *(=yellow body)*** contains the remnants of mature follicle after ovulation. The corpus luteum produces progesterone, estrogens, relaxin, and inhibin until it degenerates into fibrous scar tissue called **the corpus albicans (=white body).**

Function of the ovaries:

The ovaries have **two functions** - "production" and ovulation of oocytes and the production and secretion of hormones.

- The ovary is attached to the broad ligament by a short fold of peritoneum, called the **mesovarium**

4) Fallopian tubes:

Structure, Position

- These are muscular narrow tubes **extend laterally** from the **cornua of the** uterus toward the wall of the pelvis.
- Its long is 8- 14-cm.
- Similar to the uterus, composed of serosal, muscular, and mucosal layers .Muscular layer contains an external longitudinal layer and an internal circular layer of muscle. The mucous is composed of columnar

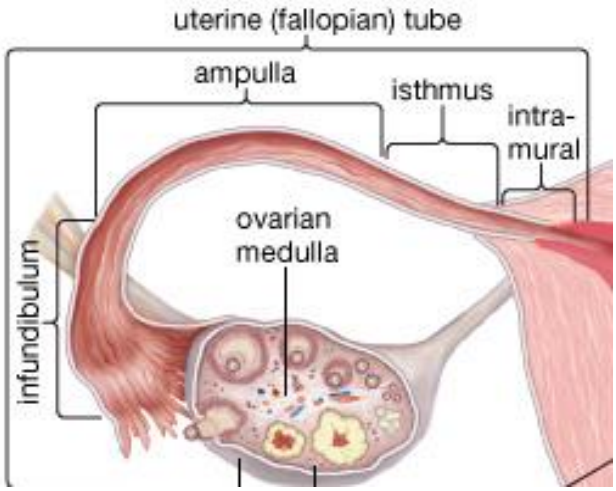

- The uterine tube is divided into four parts.: fimbriae , infundibulum, ampulla, isthmus,

1. Interstitial Portion:
   - It is 2.5 cm long, lies within the wall of the uterus. Its lumen is 1mm (the narrowest part).
2. The Isthmus of the Uterine Tube
   - This is the short (about 2.5 cm), narrow, thick-wall, part of the uterine tube.
   - It enters the cornu of the uterus.
3. The Ampulla of the Uterine Tube
   - This begins at the medial end of the infundibulum.
   - It is in this tortuous part that fertilization of the oocyte by a sperm usually occurs.The ampulla is the widest and longest part of the uterine tube, making up over half of its length.
4. Infundibular:
   - It is the funnel-shaped end that is composed of many processes known as fimbrial.

Fimbriae:

- Latera fringes have 20 to 30 fimbriae.
- These finger-like processes spread over the surface of the ovary, and a large one, the ovarian fimbria, is attached through the Uterine Tube into the ampulla.

Layers of Fallopian Tubes

- The lining is a mucous membrane and in this lining are goblet cells, which produce a secretion, containing glycogen to nourish the ovum.
- Beneath the lining is a layer of vascular connective tissue.
- The muscle coat consists of smooth muscles that cause peristaltic movement of the fallopian tubes to the ovary.
- During ovulation the fimbriae trap the oocyte and sweep it.

Functions of the Uterine Tube:

1. The epithelial layer contains **ciliated cells**, which promote ova **transport** toward the uterus.
2. The uterine tubes **carry oocytes** from the **ovaries** and **sperm cells** from the uterus to the **fertilization site** in the **ampulla of the uterine tube**. The fertilized egg then moves to the uterus, where it implants into the lining of the uterine wall.

https://cdn.britannica.com/05/55705-050-DE695AC2/uterus-bladder-system-rectum-child-egg.jpg

Breasts

- Organs of sexual arousal

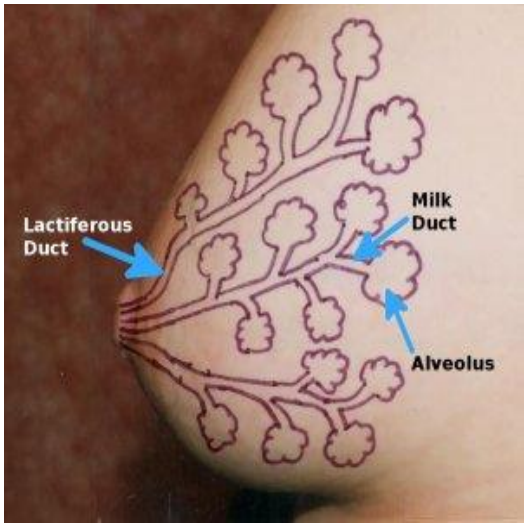

- Contain mammary glands, connective tissue
- Each breast contain 15-25 clusters called lobes
- Each lobule is connected by ducts that open into the nipples
- The nipples are made up of erectile tissue
- The pigmented around the nipples are called the areola.
- Breast size is determined primarily by heredity OR by bexisting fat and glandular tissue.
- Breasts may exhibit cyclical changes, including increased swelling and tenderness prior to menstruation.
- Benign breast changes refer to fibrocystic disease.
- Lumps or masses those are noncancerous.

References

1. Cunningham, F. G., Leveno, K. J., Bloom, S. L., Dashe, J. S., Hoffman, B. L., Casey, B. M., & Spong, C. Y. (Eds.). (Current Edition). Williams Obstetrics. McGraw-Hill Education. (Considered a foundational reference in obstetrics, covering physiological changes in detail).
2. Lowdermilk, D. L., Perry, S. E., Cashion, M. C., & Alden, K. R. (Eds.). (Current Edition). *Maternity and Women's Health Care*. Elsevier. (Provides a comprehensive nursing perspective on maternal and child care, including physiological changes).
3. Ricci, S. S., Kyle, T., & Carman, S. (Current Edition). *Maternity and Pediatric Nursing*. Wolters Kluwer.
4. **National Institutes of Health (NIH) - PubMed Central:** (pmc.ncbi.nlm.nih.gov) An excellent database for searching recent scientific articles on "Physiological changes during pregnancy" or "Maternal adaptations in pregnancy."
5. **American College of Obstetricians and Gynecologists (ACOG):** (www.acog.org) Provides guidelines and resources for professionals and patients.
6. **World Health Organization (WHO):** (www.who.int) Offers global guidelines on maternal care and reproductive health.